

# Hypoperfusion without Stroke Alters Motor Activation in the Opposite Hemisphere

John W. Krakauer, MD,<sup>1</sup> Petya D. Radoeva, BA,<sup>1</sup> Eric Zarah, PhD,<sup>2</sup> Jennifer Wydra, BA,<sup>3</sup> Ronald M. Lazar, PhD,<sup>1,4</sup> Joy Hirsch, PhD<sup>3,5</sup> and Randolph S. Marshall, MD<sup>1</sup>

---

To specifically investigate the effect that large-vessel disease may have on cortical reorganization, we used functional magnetic resonance imaging to study patients with unilateral hemispheric hypoperfusion and impaired vasomotor reactivity from critical internal carotid or middle cerebral artery disease but without stroke. We hypothesized that when these patients used the hand contralateral to the hypoperfused hemisphere they would show unique activation in motor-related areas of the normally perfused hemisphere, that is, ipsilateral activation. We found that normal performance of two motor tasks was associated with increased ipsilateral hemispheric activation in the patients compared with age-matched controls. In addition, although task difficulty had an effect on ipsilateral activation, the increased ipsilateral activation seen in patients was not dependent on task difficulty. Our findings demonstrate that hemodynamic compromise alone is sufficient to cause atypical ipsilateral activation. This activation may serve to maintain normal motor performance.

Ann Neurol 2004;56:796–802

---

Over the past decade, functional brain imaging has been used increasingly to investigate mechanisms of motor recovery after stroke. A consistent finding in the earlier studies was that patients showed prominent activation in the ipsilateral hemisphere during the execution of simple motor tasks with the affected limb.<sup>1–3</sup> This was in contrast to healthy subjects who had activation predominantly in the expected contralateral motor cortex. Although these results suggested a role for the ipsilateral hemisphere in motor performance after stroke, more recent longitudinal imaging studies<sup>4–6</sup> show that activation in the ipsilateral hemisphere correlates with severity of motor impairment and may disappear as motor recovery occurs. The longitudinal studies to date suffer, however, from two important limitations. First, there has been focus almost exclusively on small vessel subcortical strokes. Second, a difference in motor performance between patients with stroke-induced hemiparesis and controls may, in of itself, alter activation patterns and thus confound results.<sup>7</sup>

To specifically address the influence of large-vessel disease on functional motor activation patterns, we studied patients with cortical hypoperfusion caused by large-vessel stenosis or occlusion. A consequence of our

study design was that despite the presence of a compromised physiological state (hemodynamic insufficiency) there was no reason to expect a performance difference between the two groups, because the patients had never suffered a stroke and had normal neurological examinations at the time of imaging. Thus, our design was not expected to suffer from the confound of differential performance between patients and controls.

We hypothesized that patients with exhausted vasomotor reactivity (VMR) due to large-vessel disease would show ipsilateral reorganization despite not having had a stroke. This hypothesis is supported by the finding that patients with unilateral critical large-vessel disease can have cognitive impairments, suggestive of injury to that hemisphere, that are not attributable to focal lesions.<sup>8,9</sup> A correlation has also been found between degree of neural activity and cerebral blood flow (CBF) in patients with unilateral major cerebral artery occlusion.<sup>10</sup>

In healthy subjects, ipsilateral activation during the performance of finger/hand movement tasks is dependent on task complexity/difficulty.<sup>11–14</sup> Our secondary hypothesis was that the mechanism that leads to ipsilateral activation from exhausted VMR is separate from that caused by variations in difficulty/complexity of the

---

From the <sup>1</sup>Department of Neurology, <sup>2</sup>Cognitive Neuroscience Division, Taub Institute, Departments of <sup>3</sup>Radiology and <sup>4</sup>Neurological Surgery, Columbia University; and <sup>5</sup>Center for Neurobiology and Behavior, New York State Psychiatric Institute, New York, NY.

Received Mar 4, 2004, and in revised form Jun 25 and Aug 10. Accepted for publication Aug 10, 2004.

This article includes supplementary material available via the internet at <http://www.mrw.interscience.wiley.com/suppmat/0364-5134/suppmat/>

Published online Nov 24, 2004, in Wiley InterScience ([www.interscience.wiley.com](http://www.interscience.wiley.com)). DOI: 10.1002/ana.20286

Address correspondence to Dr Krakauer, Department of Neurology, Columbia University, 710 West 168<sup>th</sup> Street, New York, NY 10032. E-mail: [jwk18@columbia.edu](mailto:jwk18@columbia.edu)

task. If this is the case, these factors should not interact. Surprisingly, there have been no functional imaging studies that directly compare ipsilateral motor activations seen in healthy subjects with those that result from hemispheric dysfunction.

We tested subjects with two motor tasks; one required them to gently make a fist (GRIP) and the other to perform a finger sequence on a button box device (SEQ). We chose these two tasks because hand squeeze or grip has been shown in previous studies to activate almost exclusively contralateral primary motor cortex,<sup>12</sup> whereas finger sequences tend to activate additional premotor and parietal regions in both hemispheres.<sup>13</sup> Thus, the GRIP and SEQ tasks represented the lower and higher levels, respectively, of our task complexity factor.

## Subjects and Methods

### Subjects

Six right-handed patients, aged 34 to 81 years, with unilateral internal carotid artery (ICA) or middle cerebral artery (MCA) high-grade stenosis or occlusion and six right-handed age-matched controls, aged 22 to 71 years, participated in the study. There was no significant age difference between the two groups (patients,  $53.7 \pm 17.8$ ; controls,  $44.7 \pm 17.3$ ; *t* test, *p* = 0.395). All participants gave written informed consent for the study using an institutional review board–approved and Health Insurance Portability and Accountability Act –compliant protocol.

### Patient and Control Inclusion Criteria

All six patients had Doppler-confirmed large-vessel occlusion or stenosis. In addition, all had decreased VMR as determined by transcranial Doppler, as described below. Five of the patients had TIAs, attributable to the affected vessel, within 6 months of the study, and one was asymptomatic (Table 1). All the patients had normal neurological examination as determined by two neurologists, including normal rapid alternating movements, and none had evidence of infarct in the territory of the stenosed or occluded vessel by fluid-attenuated inversion recovery or diffusion-weighted magnetic resonance imaging (MRI) sequences. Transcranial

Dopplers of the posterior circulation were normal. The age-matched controls had normal neurological examination and no evidence for focal lesions on fluid-attenuated inversion recovery or DWI MRIs. Carotid and transcranial Doppler studies were hemodynamically normal in the controls. Handedness was determined using the Edinburgh inventory.

### Vasomotor Reactivity Measurements

All patients underwent continuous bilateral transcranial Doppler monitoring (Pioneer TC 4040; Nicolet Biomedical, Madison, WI) of the MCAs at an insonation depth of 50 to 56mm as described previously.<sup>15</sup> In brief, partial pressure of carbon dioxide (pCO<sub>2</sub>) was measured continuously with an in-line capnometer (Datex-Ohmeda, Helsinki, Finland) connected via snorkel mouthpiece, with the nasal airway occluded by nose clip. After 2 minutes of baseline measurements, subjects breathed a 5% CO<sub>2</sub> and air mixture (carbigen) for 2 minutes. Cerebral VMR was calculated as percentage of increase in the ipsilateral MCA mean flow velocity (MFV) per mm Hg pCO<sub>2</sub> once the MFV curve reached its highest level during the 2-minute inhalation period. The contralateral VMR was measured as a control. “Normal” VMR was defined as an increase in MCA MFV of greater than 2.0%/mm Hg pCO<sub>2</sub>, corresponding to two standard deviations below the mean of control data from a previous study.

### Motor Protocol

During functional MRI, scanning subjects performed two runs of each task with both left and right hands. During each run, they alternated 20-second task blocks with 20-second rest blocks. Three task blocks and four rest blocks were performed per run. For GRIP, subjects isometrically closed their hand into a fist at a frequency of 1Hz in synchrony with a tone heard through MR-compatible headphones. Subjects’ arms lay comfortably by their side with full weight support. For SEQ, subjects depressed buttons on a finger pad, which rested comfortably on their stomachs, in a continuous repeating sequence from digit 1 through 5 at a frequency of 1Hz, again in synchrony with the tone. The tone was also present during the rest periods. The order of the two tasks was pseudorandomized across subjects, but each task was done as a pair of runs. Subjects practiced the

Table 1. Patient Clinical Characteristics

Patient No.	Stroke	TIA Symptoms	Vessel	VMR (L/R)	Age (yr)
1	None	None	R ICA stenosis	2.5/1.2	81
2	None (TIA)	Left hemiparesis three times over 1 year	R ICA occlusion	1.2/−0.5	64
3	None (TIA)	Weakness and shaking of the right arm and hand for 1 week	L MCA stenosis	1.6/4.1	34
4 <sup>a</sup>	None (TIA)	Mild heaviness and numbness of the left arm and leg	R ICA occlusion	3.2/1.6	35
5	None (TIA)	Right transient monocular blindness	R ICA occlusion	2.4/0.2	55
6	None (TIA)	Left arm and hand weakness	R MCA stenosis	3.3/2.0	53

<sup>a</sup>Small chronic infarct in left splenium of corpus callosum + left occipital cortex.

TIA = transient ischemic attack; VMR = vasomotor reactivity (% change in mean flow velocity/mmHg pCO<sub>2</sub>, CO<sub>2</sub>); L = left; R = right.

sequence task briefly before scanning began. An investigator remained beside the scanner throughout the session to give instructions and to observe for mirror movements. All subjects had their eyes closed throughout the scanning period, and their nonmoving arm rested comfortably with the hand palm down.

### *Magnetic Resonance Data Acquisition*

A General Electric 1.5T MR scanner was used to acquire both T<sub>1</sub>-weighted anatomical images (1.5 × 1.5 × 4.5mm voxels) and T<sub>2</sub>\*-weighted MRI transverse echo planar images (EPIs) with blood oxygenation level dependent (BOLD) contrast. The following image acquisition parameters were used: 19cm field of view, 128 × 128 image matrix, 4,000 milliseconds TR, 60 milliseconds TE, and a 60-degree flip angle. Each EPI was made up of 25, 4.5mm-thick, contiguous axial slices with 0mm separation, and with the coil positioned to obtain slices through the whole brain. A total of 41 volumes were acquired continuously during each session. The first and last three volumes were discarded to allow for T1 equilibration effects.

### *Image Analysis*

**FIXED EFFECTS CONJUNCTION ANALYSIS.** Imaging data were analyzed using statistical parametric mapping (SPM99; Welcome Department of Imaging Neuroscience, <http://www.fil.ion.ucl.ac.uk/spm/>). None of the subjects moved their head more than 2mm in any direction, and there were no appreciable task-related head movements. All volumes were spatially realigned to the first volume, underwent slice-timing correction and were coregistered to the T1 image of each subject. The T1 image was normalized to a standard T1 template based on the Montreal Neurological Institute reference brain, and the normalization parameters were applied to the EPIs. The data then were spatially smoothed with an isotropic 6mm full-width half-maximum Gaussian kernel. In the patient group, left-sided hypoperfusion images were flipped to make the “right” hemisphere the hypoperfused hemisphere in all cases.

Group results were obtained by performing separate conjunction analyses with a fixed-effects model on the patient and controls groups at *p* value less than 0.001 (uncorrected for multiple comparisons). This corresponded to each individual subject map being thresholded at *t* = 0.48. This approach is more powerful than random-effects analyses for small sample sizes because it retains the sensitivity of a fixed-effects analysis while allowing the inference that a non-zero proportion of the population also has the same effect.<sup>16</sup>

**REGION OF INTEREST ANALYSIS.** To quantitatively test our hypothesis that ipsilateral sensorimotor cortical areas were activated more in the patients than in controls, we performed an independent region of interest (ROI) analysis comprised of cortical regions that have been consistently shown to be activated in motor tasks in healthy subjects. We drew five regions of ROIs using an Montreal Neurological Institute template and criteria described by Fink and colleagues<sup>17</sup>: (1) the primary and sensorimotor area (M1/S1) as the pericentral sulcal region up to the precentral and postcentral sulci; (2) lateral premotor cortex as cortex lying up to

10mm anterior of the precentral sulcus; (3) the superior parietal lobule as cortex lying superior to the intraparietal sulcus and immediately posterior to the postcentral sulcus; (4) the inferior parietal lobule as cortex lying below the intraparietal sulcus and posterior to the postcentral sulcus; and (5) the supplementary motor area as cortex above the cingulate sulcus and bounded by a plane perpendicular to the posterior commissure and a plane perpendicular to the genu of the corpus callosum.<sup>18</sup> The percentage of change in signal activity was calculated in each ROI and hypotheses tested using *t* tests significant at *p* value less than 0.05.

## **Results**

### *Hemispheric Activations Using the Contralateral Hand*

For all results, the right hand contralateral to the normally perfused left hemisphere was designated the “unaffected” hand, and the left hand contralateral to the hypoperfused right hemisphere was designated “affected” even though the hand was neurologically normal. Control subjects performed both GRIP and SEQ without observable mirror movements. For GRIP, the controls activated contralateral M1 and premotor areas and ipsilateral cerebellum. SEQ caused additional contralateral and ipsilateral activation of premotor and parietal areas (see Fig 1A and Supplementary material). These results are consistent with previous studies that have compared grip and sequence tasks.<sup>12,13</sup> There was no qualitative difference in the activation patterns for GRIP or SEQ when control subjects used their left or right hand. Notably, we did not see more prominent ipsilateral activation when subjects used their non-dominant (left) hand (see Fig 1A, first and second rows vs third and fourth rows).

All six patients had impaired VMR in one hemisphere caused by critical carotid or MCA disease and normal VMR in the opposite hemisphere (see Table 1). The patients made no observable mirror movements in either GRIP or SEQ. Performance of the GRIP and SEQ task with the unaffected hand showed similar contralateral activation to the controls (see Fig 1B, third and fourth rows). These observations were supported quantitatively by the ROI analysis, which showed no significant difference between patients and controls for activations in the left hemisphere when using the right hand in either task (*t*[10] = 1.64, two-tailed *p* = 0.12; Fig 2A).

Visual comparison of right hemisphere activation in controls and patients suggested a reduction in activation in the patients for both tasks. The ROI analysis did not, however, show a significant difference (*t*[10] = 0.96, two-tailed *p* = 0.36; see Fig 2B). Thus, unlike previous reports, we did not see a significant reduction in the BOLD response in the hypoperfused hemisphere compared with controls.

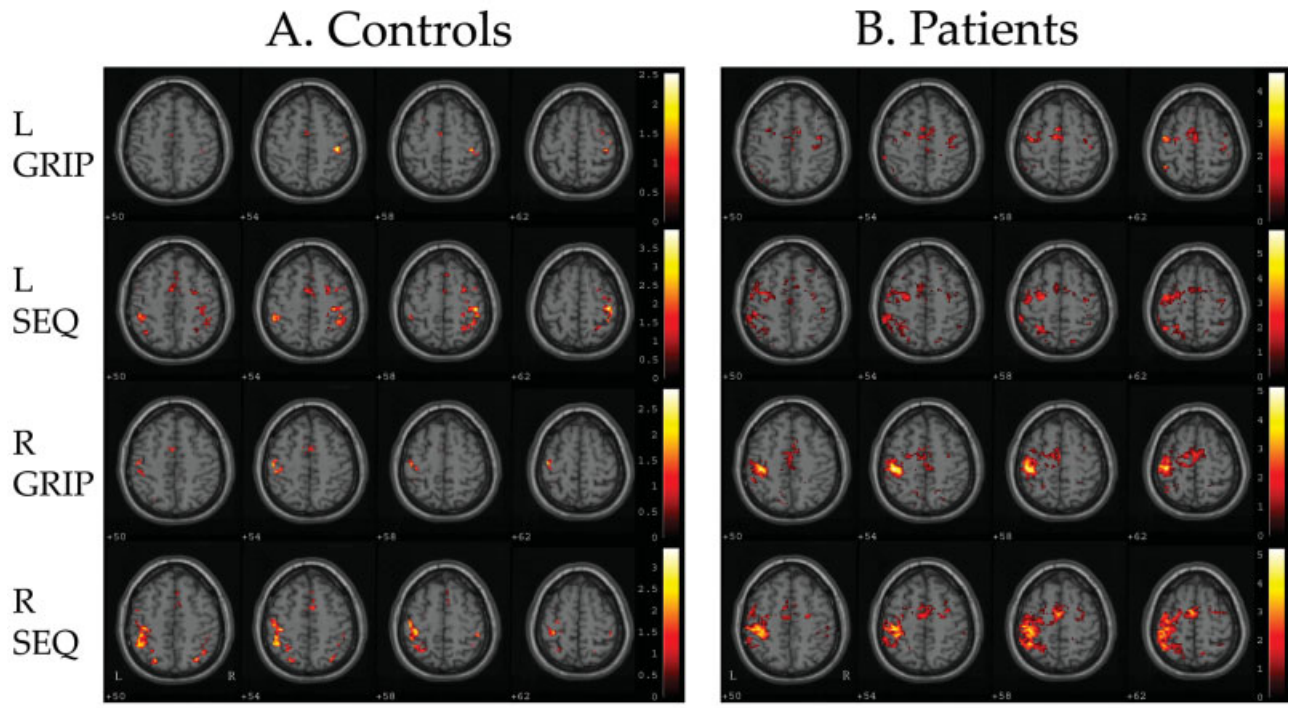


Fig 1. Axial activation maps using a fixed-effects model with conjunction analysis ( $p < 0.001$ , uncorrected). Patients using the “affected” left hand predominantly activated left (ipsilateral) areas, whereas controls predominantly activated right (contralateral) areas. Both patients and controls activated contralaterally when using the “unaffected” right hand. Color bars to the right of each condition indicate the range of activation T-values.

#### *Hemispheric Activations Using the Ipsilateral Hand*

When using the affected hand, patients showed more prominent ipsilateral activation compared with controls (see Fig 1B, first and second rows, see Supplementary material). SEQ was associated with more ipsilateral activation than GRIP. Novel ipsilateral areas included medial and lateral premotor, prefrontal, and parietal regions. In addition, whereas cerebellar activation remained ipsilateral for the controls, it was bilateral in both tasks for the patients.

We quantified our hypothesis positing increased ipsilateral activation in motor-related areas in patients with an ROI analysis showing a significantly greater degree of activation, averaged across the five ipsilateral ROIs, in the patients compared with controls ( $t[10] = 2.35$ , one-tailed  $p = 0.02$ ) (Fig 3A). As suggested by the conjunction analysis, there was a significant effect of task complexity on ipsilateral activation for both patients and controls ( $t[10] = 1.99$ , one-tailed  $p = 0.04$ ). The task by group interaction was not significant ( $F[1,10] = 0.04$ , two-tailed  $p = 0.43$ ; see Fig 3B). The lack of significant interaction between task and group suggests that hypoperfusion causes changes in ipsilateral recruitment in motor tasks through a mechanism that is separate from mechanisms sensitive to task complexity. There was no significant difference in ipsilateral activation across the same five ROIs when

controls and patients used their right hand ( $t[10] = 0.19$ , two-tailed  $p = 0.85$ ; see 3C). Thus, the difference in ipsilateral activation between patients and controls was specific to the hemisphere opposite the stenosis/occlusion.

#### **Discussion**

This study had two main findings. First, hypoperfusion in the absence of a stroke led to increased ipsilateral activation in patients compared with controls for two motor tasks. Second, the increased ipsilateral activation was separable from the effect of task difficulty. These results have important implications for determining both the pathophysiology of hemodynamic failure and the role of the ipsilateral hemisphere in motor behavior.

#### *The Effects of Hypoperfusion on Hemispheric Activation*

All the patients in this study had reduced VMR and five of the six had TIAs (see Table 1). Despite the presence of this hemodynamic insufficiency, the patients did not report any current motor difficulties, had no evidence of infarction in a motor area by structural imaging, and had normal neurological examinations, including normal rapid alternating movements of the fingers, at the time of functional imaging. Nevertheless,



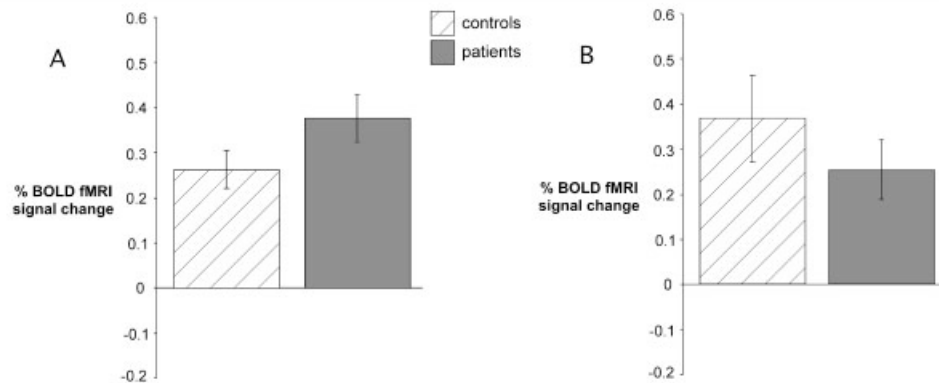


Fig 2. Region of interest (ROI) analysis. Bar graphs of contralateral hemisphere fMRI percentage signal change, averaged across all five ROIs, for controls and patients when using the “unaffected” right hand (A) and “affected” left hand (B). Differences between controls and patients were not significant. fMRI = functional magnetic resonance imaging; BOLD = blood oxygen level dependent.

we found an atypical pattern of activation by functional MRI with increased ipsilateral activation compared with age-matched controls. A similar result has been reported recently in two patients with unilateral high-grade MCA stenosis,<sup>19</sup> but small acute strokes were also present, making interpretation difficult. Unlike in recent reports,<sup>20–22</sup> we did not see a significant reduction in the BOLD response in the hypoperfused hemisphere compared with controls. This suggests that unilateral steno-occlusive disease with reduced VMR does not reliably predict reduction in the BOLD response through uncoupling of neuronal activity and local hemodynamics.

#### The Role of Activation in the Ipsilateral Hemisphere

The increased ipsilateral activation seen in our patients when they used their “affected” hand is similar to what has been described in patients after stroke<sup>23</sup> and with arteriovenous malformations.<sup>24</sup> The pres-

ence of atypical ipsilateral activation in patients without persistent motor symptoms or signs raises the interesting possibility that reorganization might be driven by motor abnormalities that, distinct from TIAs, are not symptomatic. Although there have not been studies that describe subtle motor abnormalities in patients with critical large-vessel disease, there is evidence that subtle cognitive impairment may occur in this patient population. In particular, it recently has been argued that hypoperfusion per se, and not focal lesions, can produce these cognitive deficits.<sup>9</sup> Analogously, subtle motor impairments in patients with hypoperfusion might lead to compensatory responses in the opposite hemisphere to maintain motor performance. The possibility that undetected motor impairment may result in brain activation changes in patients is supported by several examples of brain activation changes in healthy subjects when they perform motor tasks in which errors and/or improve-

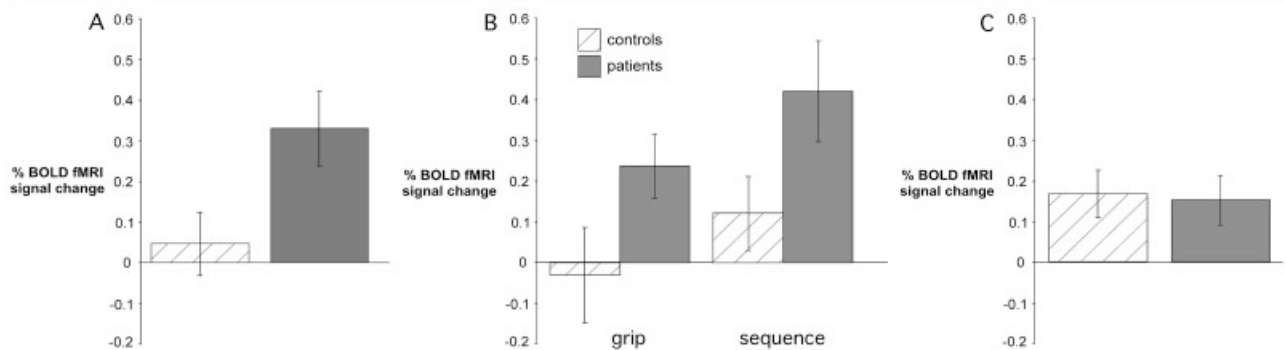


Fig 3. Region of interest (ROI) analysis. Bar graphs of ipsilateral hemisphere fMRI percentage signal change, averaged across all five ROIs, in controls and patients. (A) There was significantly greater activation in the left hemisphere of patients than controls when they moved the “affected” left hand. (B) Percentage signal change was greater in SEQ than GRIP for both controls and patients. The interaction between group (control or patient) and task complexity (GRIP or SEQ) was not significant (see Results). (C) There was no significant difference in percentage signal change in the right hemisphere between controls and patients when they used the unaffected right hand. fMRI = functional magnetic resonance imaging; BOLD = blood oxygen level dependent.

ment are not consciously detected.<sup>25,26</sup> Two recent TMS studies, one in healthy subjects<sup>27</sup> and one in patients with hemiparesis,<sup>28</sup> suggest that ipsilateral premotor cortex can maintain motor performance when contralateral motor areas are compromised.

Two alternative explanations for our findings should be considered: patients made mirror movements or the BOLD response was somehow augmented in the unaffected hemisphere. Mirror movements are an unlikely explanation. First, mirror movements were not observed. Second, the patients had normal motor examinations and would not be expected to make more mirror movements than the age-matched controls. An augmented BOLD response in the left hemisphere is also unlikely. First, we did not find significantly increased BOLD activation in the left hemisphere when patients used their right hand. Second, it has been shown that CBF, cerebral blood volume, oxygen extraction fraction, and cerebral rate of oxygen metabolism in the hemisphere opposite a carotid occlusion are not significantly different from control values.<sup>29</sup> Indeed, we did not find increased VMR in the unaffected hemisphere.

We conclude that unilateral hemodynamic insufficiency in patients with large-vessel disease causes sufficient dysfunction, either physiological or structural, to induce activity in the opposite hemisphere that may serve to maintain normal motor performance. In addition, this activity appears distinct from ipsilateral activity related to task complexity that is seen in healthy subjects. It has been proposed recently that there may be a distinction between load-dependent changes in brain activation in healthy subjects (reserve) and changes induced by disease (compensation).<sup>30</sup>

Our finding of atypical ipsilateral activation in patients without motor deficit indicates that the association of atypical ipsilateral activation with poor motor outcome<sup>6</sup> cannot be considered a general principle. The influence of hemodynamic compromise in patients with large-vessel disease should be considered in the investigation of mechanisms of stroke recovery. A pre-existing compensatory ipsilateral activation pattern might be one reason why patients with stroke due to flow failure from large-vessel disease tend to have less severe clinical manifestations than those with other stroke subtypes.<sup>31</sup>

---

This work was supported by NIH (National Institute of Neurological Disorders and Stroke, NS 02138, J.W.K., NS 02144, R.S.M.), The Suellen Jones Memorial Foundation, and The Richard and Jenny Levine Foundation.

We thank A. Barnes for help with data analysis.

---

## References

1. Chollet F, DiPiero V, Wise RJ, et al. The functional anatomy of motor recovery after stroke in humans: a study with positron emission tomography. *Ann Neurol* 1991;29:63–71.
2. Weiller C, Chollet F, Friston KJ, et al. Functional reorganization of the brain in recovery from striatocapsular infarction in man. *Ann Neurol* 1992;31:463–472.
3. Weiller C, Ramsay SC, Wise RJ, et al. Individual patterns of functional reorganization in the human cerebral cortex after capsular infarction. *Ann Neurol* 1993;33:181–189.
4. Marshall RS, Perera GM, Lazar RM, et al. Evolution of cortical activation during recovery from corticospinal tract infarction. *Stroke* 2000;31:656–661.
5. Feydy A, Carlier R, Roby-Brami A, et al. Longitudinal study of motor recovery after stroke: recruitment and focusing of brain activation. *Stroke* 2002;33:1610–1617.
6. Ward NS, Brown MM, Thompson AJ, Frackowiak RS. Neural correlates of motor recovery after stroke: a longitudinal fMRI study. *Brain* 2003;126:2476–2496.
7. Krakauer JW. Functional imaging of motor recovery after stroke: remaining challenges. *Curr Neurol Neurosci Rep* 2004;4:42–46.
8. Bakker FC, Klijn CJ, Jennekens-Schinkel A, et al. Cognitive impairment is related to cerebral lactate in patients with carotid artery occlusion and ipsilateral transient ischemic attacks. *Stroke* 2003;34:1419–1424.
9. Bakker FC, Klijn CJ, Jennekens-Schinkel A, et al. Cognitive impairment in patients with carotid artery occlusion and ipsilateral transient ischemic attacks. *J Neurol* 2003;250:1340–1347.
10. Bundo M, Inao S, Nakamura A, et al. Changes of neural activity correlate with the severity of cortical ischemia in patients with unilateral major cerebral artery occlusion. *Stroke* 2002;33:61–66.
11. Wexler BE, Fulbright RK, Lacadie CM, et al. An fMRI study of the human cortical motor system response to increasing functional demands. *Magn Reson Imaging* 1997;15:385–396.
12. Ehrsson HH, Fagergren A, Jonsson T, et al. Cortical activity in precision-versus power-grip tasks: an fMRI study. *J Neurophysiol* 2000;83:528–536.
13. Ehrsson HH, Kuhtz-Buschbeck JP, Forssberg H. Brain regions controlling nonsynergistic versus synergistic movement of the digits: a functional magnetic resonance imaging study. *J Neurosci* 2002;22:5074–5080.
14. Hummel F, Kirsammer R, Gerloff C. Ipsilateral cortical activation during finger sequences of increasing complexity: representation of movement difficulty or memory load? *Clin Neurophysiol* 2003;114:605–613.
15. Marshall RS, Rundek T, Sproule DM, et al. Monitoring of cerebral vasodilatory capacity with transcranial Doppler carbon dioxide inhalation in patients with severe carotid artery disease. *Stroke* 2003;34:945–949.
16. Friston KJ, Holmes AP, Price CJ, et al. Multisubject fMRI studies and conjunction analyses. *Neuroimage* 1999;10:385–396.
17. Fink GR, Frackowiak RS, Pietrzyk U, Passingham RE. Multiple nonprimary motor areas in the human cortex. *J Neurophysiol* 1997;77:2164–2174.
18. Immisch I, Waldvogel D, van Gelderen P, Hallett M. The role of the medial wall and its anatomical variations for bimanual antiphase and in-phase movements. *Neuroimage* 2001;14:674–684.
19. Hund-Georgiadis M, Mildner T, Georgiadis D, et al. Impaired hemodynamics and neural activation? A fMRI study of major cerebral artery stenosis. *Neurology* 2003;61:1276–1279.

20. Bilecen D, Radu EW, Schulte AC, et al. fMRI of the auditory cortex in patients with unilateral carotid artery steno-occlusive disease. *J Magn Reson Imaging* 2002;15:621–627.
21. Hamzei F, Knab R, Weiller C, Rother J. The influence of extra- and intracranial artery disease on the BOLD signal in fMRI. *Neuroimage* 2003;20:1393–1399.
22. Rossini PM, Altamura C, Ferretti A, et al. Does cerebrovascular disease affect the coupling between neuronal activity and local haemodynamics? *Brain* 2004;127:99–110.
23. Cramer SC, Nelles G, Benson RR, et al. A functional MRI study of subjects recovered from hemiparetic stroke. *Stroke* 1997;28:2518–2527.
24. Alkadhi H, Kollias SS, Crelier GR, et al. Plasticity of the human motor cortex in patients with arteriovenous malformations: a functional MR imaging study. *AJNR Am J Neuroradiol* 2000;21:1423–1433.
25. Desmurget M, Grea H, Grethe JS, et al. Functional anatomy of nonvisual feedback loops during reaching: a positron emission tomography study. *J Neurosci* 2001;21:2919–2928.
26. Willingham DB, Salidis J, Gabrieli JD. Direct comparison of neural systems mediating conscious and unconscious skill learning. *J Neurophysiol* 2002;88:1451–1460.
27. Lee L, Siebner HR, Rowe JB, et al. Acute remapping within the motor system induced by low-frequency repetitive transcranial magnetic stimulation. *J Neurosci* 2003;23:5308–5318.
28. Johansen-Berg H, Rushworth MF, Bogdanovic MD, et al. The role of ipsilateral premotor cortex in hand movement after stroke. *Proc Natl Acad Sci USA* 2002;99:14518–14523.
29. Derdeyn CP, Videen TO, Fritsch SM, et al. Compensatory mechanisms for chronic cerebral hypoperfusion in patients with carotid occlusion. *Stroke* 1999;30:1019–1024.
30. Stern Y. The concept of cognitive reserve: a catalyst for research. *J Clin Exp Neuropsychol* 2003;25:589–593.
31. Pessin MS, Hinton RC, Davis KR, et al. Mechanisms of acute carotid stroke. *Ann Neurol* 1979;6:245–252.